

A Patient with Asbestos-Induced Lung Cancer Complicated by Silicosis

Takumi KISHIMOTO* and Kaho TSUDA

Department of Internal Medicine, Okayama Rousai Hospital, 1–10–25 Chikkomidorimachi Okayama, 702-8055, Japan

Received December 4, 2000 and accepted February 26, 2001

Abstract: A 76-year-old male died of lung cancer. At first, he was diagnosed as a silicosis, because he had worked for 30 years as a caster in shipyard and large opacities detected by chest x-ray and CT scanning. After the operation of lung cancer, numerous asbestos bodies were observed in the operated lung tissues. The detailed occupational inquiry revealed his asbestos use as a caster in shipyard. Early stage of asbestosis was suspected by chest CT scanning, but not definitely diagnosed in premortal examinations. Asbestosis, pleural plaques, silicosis and large cell carcinoma of the lung were histopathologically confirmed at the autopsy. A patient with asbestos-induced lung cancer complicated by silicosis was rarely published in the literature.

Key words: Caster, Lung cancer, Asbestosis, Pleural plaque, Silicosis

Introduction

Among the cases of pneumoconiosis in Japan, the incidence of silicosis is prevalent high mainly in mines and coal miners. On the other hand, cases of asbestosis have been reported in only limited working places such as asbestos textile factories and shipyards. There have been few case reports of silicosis complicated by pulmonary asbestosis. We present a case of shipyard caster with large opacities due to silicosis in whom pulmonary asbestosis was histologically demonstrated by the presence of pleural plaques due to asbestos. This patient is reported with a review of the literature.

Case Report

The patient was a 76-year-old male with cough and sputum. Smoking history was 20 cigarettes per day for 45 years. He had worked as a caster in a shipyard for 30 years since 1955. Casters in shipyards often produce long tubes. To reduce distortion, he had placed asbestos on sand molds, using asbestos together with silica sand.

He developed cough and sputum in July, 1999 and received

symptomatic therapy in a local hospital. However, the symptoms did not improve, and he was referred to our department and admitted. On admission, fine crackles were heard in the bilateral posterior lower lung fields, and clubbed fingers were observed. Chest X-ray films showed a large shadow probably due to silicosis in the right upper lung field and a tumor-like shadow in the left hilum (Fig. 1). CT scanning of the chest revealed large shadows in both the right upper and left upper lung fields (Fig. 2). The tumor in the left hilum observed on chest X-ray films was present in the left S6 (Fig. 3) in contact with the pleura. The left hilar lymph nodes were swollen. These images suggested primary lung cancer. In the bilateral lower lung fields, subpleural curvilinear shadows which suggest the early stage of asbestosis (Fig. 4) were observed. Blood examination showed increased CEA (5.8 ng/ml) as a tumor marker but no other abnormalities. Blood gas analysis revealed almost normal values (PaO₂, 88.0 mmHg; PaCO₂, 41.6 mmHg). Lung function tests showed a %VC of 92% and an FEV_{1.0}% of 67.8%, suggesting slight obstructive impairment. To make a definite diagnosis for the tumor in the left S6, transbronchial lung biopsy was performed. This tumor was diagnosed as non-small cell lung carcinoma. Though the stage was IIIa (T2, N2, M0), resection of the left lower lung was performed

*To whom correspondence should be addressed.

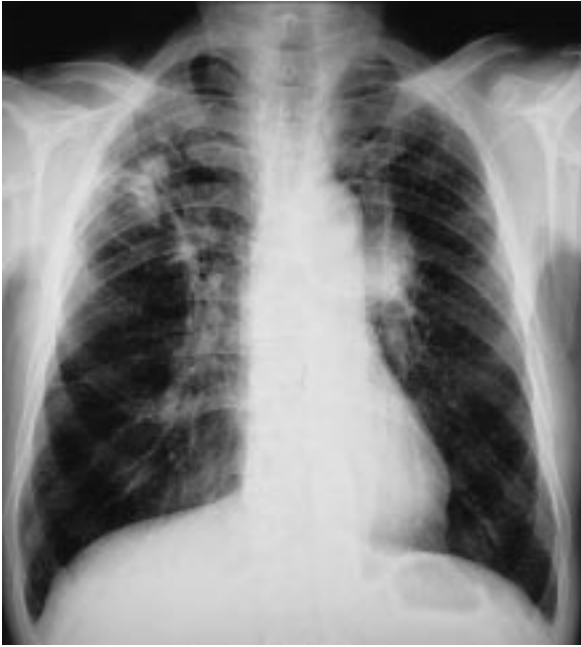

Fig. 1. This figure shows the chest x-ray at his admission.

Mass shadows are observed in the right upper lung field and left hilar area.

due to strong desire of his family and the absence of marked pulmonary dysfunction. However, the tumor had already extrapleurally disseminated, and metastasis to the mediastinal lymph nodes was definite, the surgery was limited to non-absolute resection. Histological examination of surgical specimens of the lung cancer tissue showed large cell carcinoma. Numerous asbestos bodies were confirmed in both the normal lung tissue and lung cancer tissue (Fig. 5a, b). He developed acute pneumonia (MRSA pneumonia) 2 months after surgery and died of respiratory failure.

Autopsy revealed marked progression of lung cancer and metastasis to organs in the entire body including the opposite lung. The large shadows in the bilateral upper lung fields on CT images were histologically confirmed to be due to silicosis. Around these shadows, many silicotic nodules were observed (Fig. 6). Furthermore, numerous asbestos bodies were observed around silicotic nodules (Fig. 7). In areas showing fibrous changes in the bilateral lower lung fields, findings consistent with pulmonary asbestosis were obtained (Fig. 8), and pleural plaques could be also macroscopically confirmed. When lung tissue (dry weight, 1 g) was dissolved in sodium hypochlorite and filtered using a Millipore filter according to Matsuda's method¹⁾, 28,000 asbestos bodies were observed. Pathological diagnosis was asbestos-induced primary lung cancer complicated by silicosis.

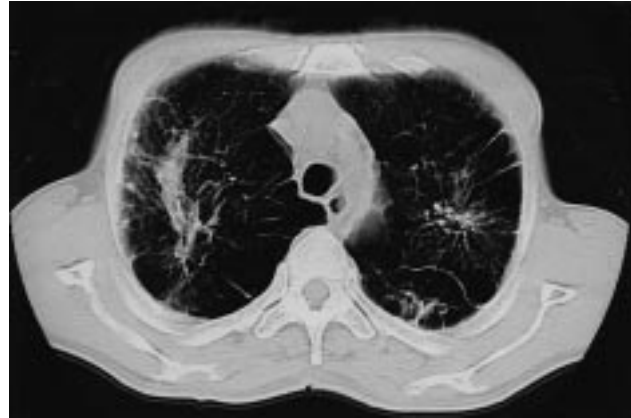


Fig. 2. Chest CT scanning shows a typical large opacities induced silicosis in the upper lung field and left upper lung field also.

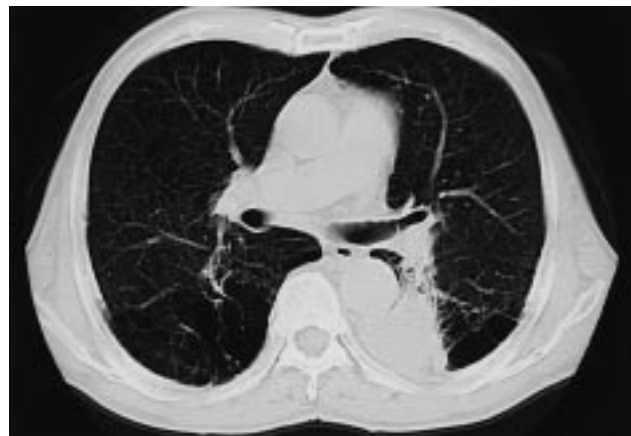
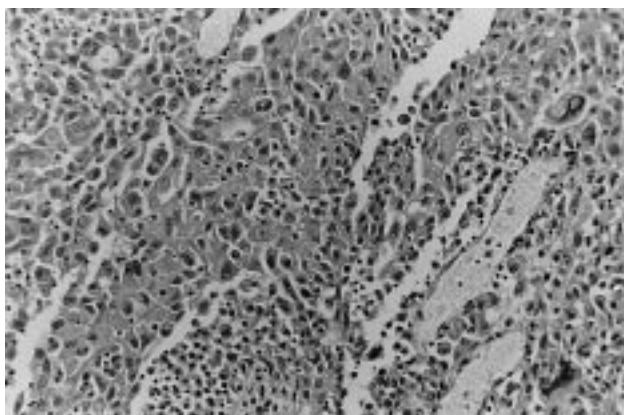


Fig. 3. Chest CT scanning in the carinal level shows a large mass shadow suggesting lung cancer in the left S6 area.

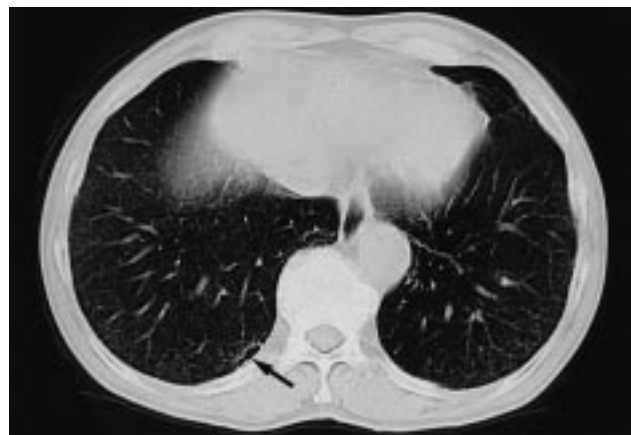

Fig. 4. Chest CT scanning in the lower level shows fibrous changes (arrow) in the posterior area.

a



b

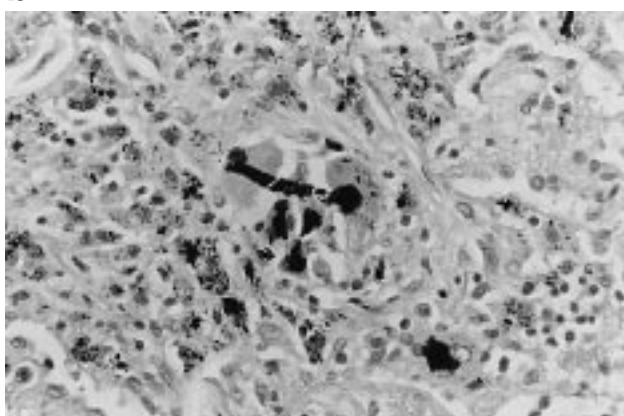


Fig. 5a. The histology of the lung tumor shows large cell carcinoma.
Fig. 5b. An asbestos body was detected in the tissue of the cancer.

Discussion

Asbestos exposure is well known to induce primary lung cancer. On the other hand, the International Agency for Research on Cancer (IARC) recently classified crystalline silica as a human carcinogen²⁾. However, no definite international consensus has been obtained concerning about the carcinogenesis due to silica³⁾.

We^{4,5)} previously reported a high incidence of lung cancer due to asbestos exposure among shipbuilding workers. The major occupations types of the patients complicated lung cancer were riggers, plumbers, and welders. The patient reported in this study had worked as a caster in a shipyard for 30 years. Casting is a process to produce parts of ships by pouring metals into sand molds, and asbestos is not generally used in this process. The primary component of dust in this process is silica, and thus, silicosis often develops. However, by detailed occupational inquiry, long tubes are often produced in casting in shipyards, and their production

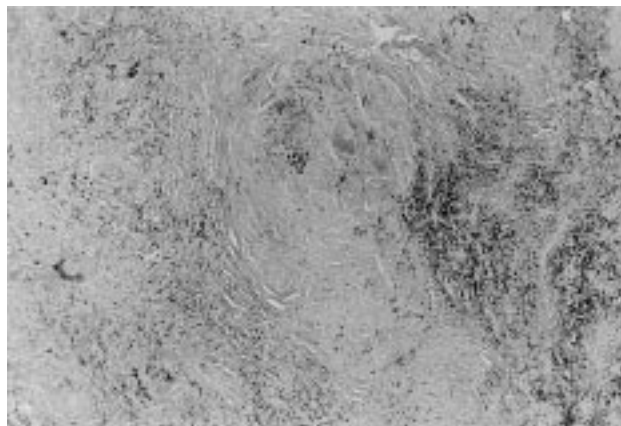


Fig. 6. The right upper lung tissue shows silicotic nodules by the light microscopy of low magnification.

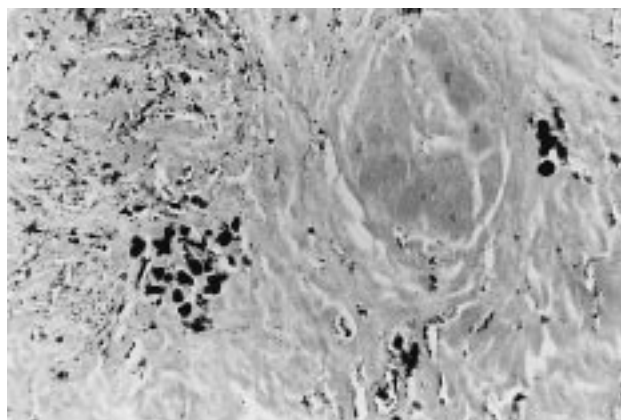


Fig. 7. Many asbestos bodies are observed in and around silicotic nodule.

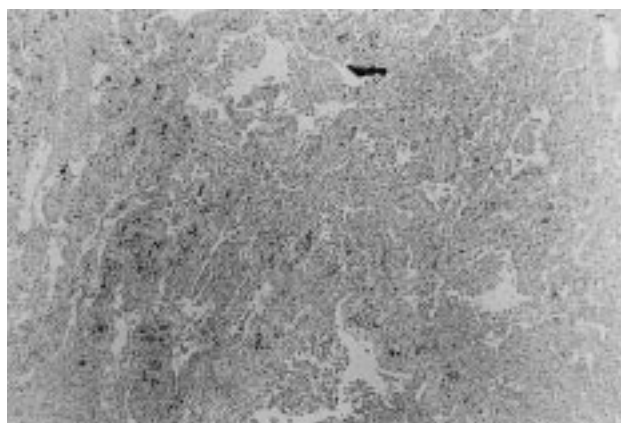


Fig. 8. The histology of the lung obtained in the lower lung shows fibrous changes which are compatible to asbestosis.

includes a process in which asbestos is placed on molds to reduce distortion. Chest X-ray examination and CT scanning of this case showed large shadows probably due to silicosis in the bilateral upper lung fields, which were histologically confirmed. But definite pleural plaques and typical pulmonary fibrosis (honey combing) were not observed on chest CT images, suggesting pulmonary asbestosis. Therefore a premortal definite diagnosis of asbestosis could not be made. Autopsy revealed definite pleural plaques and pathological findings consistent with pulmonary asbestosis. In addition, 28,000 asbestos bodies/g (dry weight) of pulmonary tissue, which corresponds to occupational asbestos exposure, were detected. According to the Helsinki criteria, an item for the definite diagnosis of asbestos lung cancer is 5,000 asbestos bodies/g (dry weight) of pulmonary tissue. Our patient fulfilled this criterion. Histopathological examination also showed numerous asbestos bodies around silicotic nodules. These findings suggested that mixed dust of silica and asbestos induced pneumoconiosis in this patient. We⁶⁾ and Yasui *et al.*⁷⁾ reported about the detection of asbestos bodies indicating occupational exposure in the lungs of patients with silicosis. But we could not confirm the histological pulmonary asbestosis in these previous cases with silicosis. In premortal examinations of this case, we failed to diagnose definite asbestosis, because of the absence of pleural plaque or asbestosis on his chest X-ray. As for the chest X-ray, the grade of asbestosis for this patient was 0/1 from the ILO criteria of pneumoconiosis in 1980. After postmortem examination, this patient was diagnosed as silicosis and asbestosis (silico-asbestosis). A conventional definition of asbestos lung cancer was lung cancer in patients with pulmonary asbestosis. However, several studies^{8,9)} have indicated no association between carcinogenicity and fibrogenicity of asbestos, and the presence of pleural plaques as an important finding of asbestos-induced lung cancer¹⁰⁻¹⁴⁾. We have suggested the importance of pleural plaques in patients with lung cancer¹⁵⁾. This suggestion has been supported by Egilman¹¹⁾ and Hillerdal⁹⁾ in the 1990s. Indeed, in this patient with pulmonary asbestosis, a definite diagnosis of pulmonary asbestosis could not be made though chest CT scanning showed subpleural curvilinear shadows¹⁶⁾. Pleural plaques are readily diagnosed by chest CT at present. In this patient, we could easily detect pleural plaques at autopsy, but could not detect by chest CT scanning. At autopsy, pulmonary fibrosis and pleural plaques were easily detected. We should do autopsy as the cases who had occupational histories of asbestos exposure.

Shida *et al.*¹⁷⁾ reported that patients with mixed dust pneumoconiosis (MDP) increased recently according to the

change of working environments with low concentration dust, and then the typical silicotic nodules show low as before. This type of pneumoconiosis induces fibrotic changes in the bilateral inferior posterior lung fields, showing large shadows as observed in this patient. The images in this patient were similar to those of MDP. However, based on a substantial amount of asbestos bodies and pulmonary fibrotic changes, a diagnosis of pulmonary asbestosis, not MDP, could be made. We speculate that cases of silicosis complicated by asbestosis in shipyards may be more common than ever recognized, and such cases will also appear in the future, and therefore, intend to perform further studies. This patient had been exposed to asbestos dust in his working place for more than 10 years and had lesions consistent with pulmonary asbestosis in the lungs and pleural plaques. In addition, 28,000 asbestos bodies/g dry weight of pulmonary tissue were detected. He was also a heavy smoker with Brinkmann index of 900. Asbestos exposure and smoking were the important factors for the appearance of lung cancer. This case was compensated as entitled to Japanese compensation for industrial accidents for asbestos lung cancer. However, he was not entitled to this compensation for silicosis because his silicosis was PR4A and F(+) due to absence of respiratory failure and classified as management 3. Crystalline silica was classified as a carcinogen by IARC in 1997 because of the large body of epidemiologic literature¹⁸⁾. In Japan, silica-induced lung cancer without severe pulmonary function or large opacities which occupied more than 1/3 of unilateral lung field was not to be compensated for industrial accidents, because crystalline silica has been to have not a definite carcinogenicity by the result of the recent Japanese professional meeting. Therefore, the clarification of asbestos exposure in this patient was of great value for the compensation.

References

- 1) Matsuda M (1975) A study of the asbestos body: detection of the asbestos body from the autopsy lung. *Jpn J Thorac Dis* **13**, 40-3 (in Japanese with English abstract).
- 2) International Agency for Research on Cancer (IARC) (1997) Evaluation of carcinogenetic risks to humans. Silica, some silicates, coal dust, and para-aramid fibrils. Volume 68. Lyon, France: IARC Publications. to a recent working group report. *J Occup Environ Med* **42**, 704-20.
- 3) Hessel PA, Gamble JF, Gee JBL, Ginbbs G, Green FHY, Morgan WKC, Mossman BT (2000) Silica, silicosis

- and lung cancer: a response to a recent working group report. *J Occup Environ Med* **42**, 704–20.
- 4) Kishimoto T, Yamamoto H (2000) Clinical evaluation of asbestos-induced lung cancer in Okayama Rousai Hospital. *Jpn J Occup Trauma Med* **48**, 255–8 (in Japanese with English abstract).
 - 5) Kishimoto T, Okada K (1988) The relationship between lung cancer and asbestos exposure. *Chest* **94**, 486–90.
 - 6) Kishimoto T, Ugaki M (1994) Evaluation of asbestos exposure for cases of silicosis. *Jpn J Trauma Occup Med* **42**, 217–20 (in Japanese with English abstract).
 - 7) Yasui K, Endou Y, Hara I, Morinaga K, Yamamoto A, Sakatani M, Yokoyama K, Sera Y, Kohyama N (1991) Assessment of occupational asbestos exposure by counting asbestos fibers in the 20 μ m thickness of lung tissue using analytical electron microscopy. *Jpn J Trauma Occup Med* **39**, 47–56 (in Japanese with English abstract).
 - 8) Wilkinson P, Hansell DM, Janssens J, Rubens M, Rudd RM, Taylor AN (1995) Is lung cancer associated with asbestos exposure when there are no small opacities on the chest radiograph? *Lancet* **345**, 1074–8.
 - 9) Hillerdal G, Henderson DW (1997) Asbestos, asbestosis, pleural plaques and lung cancer. *Scand J Work Environ Health* **23**, 93–103.
 - 10) Finkelstein MM (1997) Radiographic asbestosis is not prerequisite for asbestos-associated lung cancer in Ontario asbestos-cement workers. *Am J Ind Med* **32**, 341–8.
 - 11) Egilman D, Reinert A (1996) A. Lung cancer and asbestos exposure: asbestosis is not necessary. *Am J Ind Med* **30**, 398–406.
 - 12) Bianchi C, Brollo A, Ramani L, Zuch C (1999) Asbestos exposure in lung carcinoma: A necropsy-based study of 414 cases. *Am J Ind Med* **36**, 360–4.
 - 13) Bianchi C, Brollo A, Zuch C (1997) Pleural plaques as risk indicators for malignant pleural mesothelioma: A necropsy-based study. *Am J Ind Med* **32**, 445–9.
 - 14) Weiss W (1993) Asbestos-related pleural plaques and lung cancer. *Chest* **103**, 1854–9.
 - 15) Kishimoto T, Ono T, Okada K, Ito H (1988) Relationship between number of asbestos bodies in autopsy lung and pleural plaques on chest X-ray film. *Chest* **95**, 549–52.
 - 16) Akira M, Yokoyama K, Yamamoto S, Higashihara T, Morinaga K, Kita N, Morimoto S, Ikezoe J, Kuzuka T (1991) Early asbestosis: evaluation with high-resolution CT. *Thoracic Radiol* **178**, 409–16.
 - 17) Shida H, Chiyotani K, Honma K (1996) Radiological and pathologic characteristics of mixed dust pneumoconiosis. *Radio Graphics* **16**, 483–98.
 - 18) Smith AH, Lopipero PA, Barroga VR (1995) Meta-analysis of studies of lung cancer among silicosis. *Epidemiology* **6**, 617–24.